

## Da Vinci-assisted abdominal cerclage

Larry Barmat, M.D.,<sup>a</sup> Gretchen Glaser, M.D.,<sup>a</sup> George Davis, D.O.,<sup>b</sup> and Frank Craparo, M.D.<sup>a</sup>

<sup>a</sup> Abington Memorial Hospital, Abington, Pennsylvania; and <sup>b</sup> University of Medicine and Dentistry of New Jersey, Sewell, New Jersey

**Objective:** To report the first placement of an abdominal cervicoisthmic cerclage using the da Vinci robot.

**Design:** Case report.

**Setting:** Tertiary-care hospital.

**Patient(s):** A 39-year-old female with a history of cervical insufficiency who required a cerclage and was not a candidate for transvaginal cerclage placement.

**Intervention(s):** Abdominal cervicoisthmic cerclage placement using the da Vinci robot.

**Main Outcome Measure(s):** Ability to safely and successfully place an abdominal cerclage using the da Vinci robot.

**Result(s):** Abdominal cerclage was successfully placed using the da Vinci robot. The patient had minimal blood loss and was discharged to home on the same day as surgery.

**Conclusion(s):** Da Vinci robot-assisted abdominal cerclage placement is an innovative application of robotic surgery and may alter the standard of care for women who require this surgery. (Fertil Steril® 2007;88:1437.e1–3. ©2007 by American Society for Reproductive Medicine.)

**Key Words:** da Vinci robot, cervical insufficiency, abdominal cerclage, cervical incompetence

Cervical insufficiency (previously known as cervical incompetence) is characterized by painless cervical dilation and pregnancy loss in the second trimester. By rough estimates, this condition affects 1% of all pregnancies and up to 8% of those with second- and early third-trimester pregnancy losses (1). Although there is no standardized method to detect cervical insufficiency, studies have assessed cervical length by ultrasound or physical exam and obstetrical history with limited success (2). Once the presumed diagnosis of cervical insufficiency has been made, the most commonly used method to treat this disorder is a transvaginal purse string stitch around the cervix such as with the McDonald or Shirodkar techniques. The McDonald cerclage is placed by passing a suture in four to six bites around the cervix, incorporating adequate cervical stroma but without entering the endocervical canal. The Shirodkar cerclage similarly encircles the cervix beyond the internal os but involves dissecting the vaginal mucosa from the cervix and taking two larger bites through the cervical stroma (3–5). When a patient has minimal cervical tissue present in the vagina or other complications that make transvaginal cerclage placement contraindicated, transabdominal cerclage placement may be warranted.

The traditional approach for an abdominal cerclage is via an open laparotomy incision requiring an inpatient hospital stay

Received July 6, 2007; revised and accepted September 14, 2007.

Reprint requests: Larry Barmat, M.D., Abington Reproductive Medicine, 1245 Highland Avenue, Suite 404, Abington, PA 19001 (FAX: 215-887-3291; E-mail: lbarmat@comcast.net).

and the associated morbidities of an open procedure. Although there have been some case reports using laparoscopy, because of the limitations of laparoscopy, this has not gained widespread popularity (6–8). Therefore, to bridge the gap between traditional open surgery and the limitations of conventional laparoscopy, we report the first use of the da Vinci robotic system (da Vinci Surgical System, Intuitive Surgical, Inc., Sunnyvale, CA) for the placement of an abdominal cerclage.

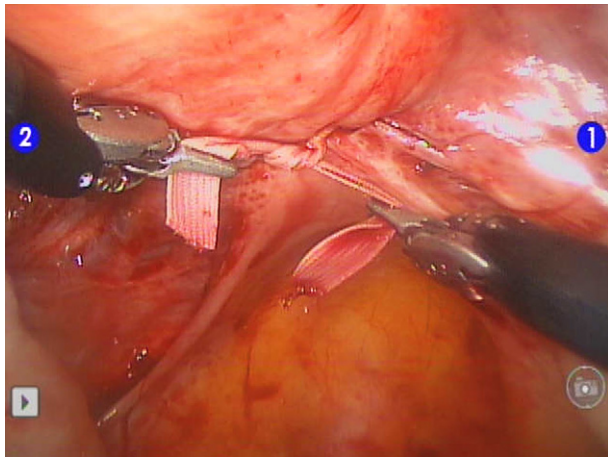
### CASE REPORT

A 39-year-old female, gravida 1, para 0-1-0-0, initially presented to our practice in 2002 at the age of 34 with 16 months of primary infertility. Her menstrual cycles were regular at 28-day intervals with 5 days of menstrual flow, and she noted mild dysmenorrhea but no other pelvic complaints. The patient's gynecologic history was significant for a cold knife cone in 1998, with final pathology of a 3.5 × 2.5 cm specimen and histopathologic diagnosis of cervical intraepithelial neoplasia II extending into the endocervical glands with clean margins. She also reported a 5-year history of herpes simplex virus with no recent outbreaks. The rest of her history was unremarkable. The patient's husband was noted to have a variable mild male factor and a normal urologic evaluation.

The patient's initial physical exam was remarkable for a nearly absent cervix and cervical stenosis. The patient and her husband attempted five unsuccessful Clomid (Merrell Pharmaceuticals Inc., Subsidiary of Aventis Pharmaceuticals Inc., Kansas City, MO) and intrauterine insemination cycles and then proceeded to IVF.

## FIGURE 1

The da Vinci robot facilitates intracorporeal knot tying and allows complete, precise placement of an abdominal cerclage.



Barmat. Da Vinci robot-assisted abdominal cerclage. *Fertil Steril* 2007.

In September 2004, at the age of 36, the patient underwent her first IVF cycle. She was treated with luteal lupron 0.5 mg reduced to 0.25 mg and 450 IU of hMG. Her peak E<sub>2</sub> was 1855 pg/mL with 17 oocytes retrieved, 16 mature, and 14 fertilized by intracytoplasmic sperm injection. She had three embryos transferred on day 3 and six blastocysts frozen. She conceived with a twin gestation.

The patient's history of cold knife cone and extremely short cervix on exam prompted close monitoring with transvaginal ultrasound and physical examination. At 16 weeks' gestation, the patient was noted to have a shortened cervix on ultrasound (1.5 cm, down from 2.7 cm on previous ultrasound) and was evaluated for cerclage but found not to be a candidate secondary to dearth of intravaginal cervical tissue. The patient was instructed by her primary obstetrician-gynecologist and maternal fetal medicine (MFM) specialist to remain on strict bed rest except for weekly appointments with MFM.

The patient's obstetrical course proceeded without further difficulty until 22 weeks' gestation when spontaneous preterm premature rupture of membranes of twin A occurred. The patient was admitted to the hospital and given antibiotics but only 7 days later developed chorioamnionitis necessitating delivery. The twins were delivered vaginally after Pitocin (JHP Pharmaceuticals, Rochester, MI) induction, and both infants died within 24 hours after birth.

After recovery, the patient sought the opinions of multiple MFM physicians throughout the country and was diagnosed with presumed cervical insufficiency based on her history of extensive cervical conization and second-trimester loss. All of the consultants agreed that the patient was a candidate for an exploratory laparotomy abdominal cerclage either dur-

ing pregnancy or prepregnancy. Therefore, the patient presented back to us for several single frozen ET attempts, all of which were unsuccessful.

The author (LB), an experienced robotic surgeon, contacted GD, who is experienced in performing abdominal cerclage and whom our patient consulted, to discuss the possibility of performing a prepregnancy abdominal cerclage using the da Vinci robot. GD accepted the offer to proctor the procedure. The patient underwent a successful da Vinci-assisted abdominal cerclage completed in 120 minutes with minimal blood loss. The vesicouterine peritoneal flap was taken down, and the uterine vessels were visualized. A hole in the broad ligament was created medial to the uterine artery at the junction of the uterosacral ligament to the cervix in a posterior to anterior direction. The 5-mm Mersilene ligature was then passed in an anterior to posterior direction with a surgeon's knot being placed posteriorly. The patient was discharged to home a few hours after the surgery and had an uncomplicated recovery returning to work in less than a week. The couple plans a fresh IVF cycle in the near future.

Our institutional review board at Abington Memorial Hospital does not require institutional review board approval for this case report because it describes a standard surgical procedure.

## DISCUSSION

Cervical insufficiency can cause devastating outcomes in otherwise viable, healthy pregnancies. Although the majority of cases of cervical insufficiency have no identifiable cause, there are some situations that seem to predispose a woman to early cervical dilation. Previous cervical surgery, traumatic laceration during prior delivery, and congenital or DES exposure-related abnormalities are commonly cited as risk factors for cervical insufficiency (5). In those patients who are not candidates for transvaginal cerclage placement, transabdominal cerclage may provide a last-resort means for otherwise high-risk women to carry their pregnancies to term.

Transabdominal cervicoisthmic cerclage placement was first described by Benson and Durfee in 1965, and the procedure has remained largely unchanged for decades, with an exploratory laparotomy being performed during early pregnancy to place the permanent suture (9). Open laparotomies require an inpatient hospital stay and the increased risk of a number of morbidities: fever, adhesion formation, blood loss, ileus, venous thrombosis, and prolonged reduced activity (10). In addition, patients will need to undergo two major surgeries for placement of the cerclage and delivery. A few obstetrician-gynecologists have performed laparoscopic abdominal cerclages to reduce these morbidities (6–8). Unfortunately, the limitations of traditional laparoscopic instruments such as the counterintuitive movements and limited range of motion create difficulties in intracorporeal knot tying and fluidity and precision of tissue dissection.

The da Vinci robot offers many of the advantages of open surgery (three-dimensional view of operative field with endowristed instruments allowing 7 degrees of freedom of motion) to enable relative ease in intracorporeal knot tying through a minimally invasive approach (Fig. 1). This allows the completion of complex surgical procedures on an outpatient basis and significant reduction in morbidities over laparotomy.

The da Vinci robot surgical system was initially approved by the Food and Drug Administration in 2000 for general laparoscopic surgery and in 2005 for gynecologic laparoscopic surgery. Its immersive stereoscopic vision display, unlimited range of motion, and system architecture of redundant sensors for maximum safety give it multiple advantages over customary laparoscopy in the delicate placement of abdominal cerclage. Additionally, the da Vinci robot system requires smaller incisions and therefore causes less postoperative pain than traditional laparotomy (10).

## CONCLUSION

There is a small subset of women for whom transvaginal cerclage is not a viable option, and these women may benefit greatly from the placement of transabdominal cerclage either before or during pregnancy. The da Vinci robot–assisted surgical approach offers a minimally invasive alternative to exploratory laparotomy and a level of intraoperative preci-

sion that traditional laparoscopy cannot match. We anticipate that with greater experience this procedure will be able to be performed in fewer than 60 minutes. The innovative approach of our procedure should serve as a template for future da Vinci robotic placements of abdominal cerclage.

## REFERENCES

1. Drakeley AJ, Roberts D, Alfirevic Z. Cervical stitch (cerclage) for preventing pregnancy loss in women. *Cochrane Database Syst Rev* 2003;1:CD003253.
2. Harger J. Cerclage and cervical insufficiency: an evidence-based analysis. *Obstet Gynecol* 2002;100:1313–27.
3. McDonald IA. Suture of the cervix for inevitable miscarriage. *J Obstet Gynecol Br Emp* 1957;64:346–50.
4. Shirodkar VN. A new method of treatment for habitual abortions in the second trimester of pregnancy. *Antiseptic* 1955;52:299–300.
5. Hankins G, Clark S, Cunningham FG, Gilstrap L. *Operative obstetrics*. Norwalk: Appleton and Lange, 1995.
6. Al-Fadhli R, Tulandi T. Laparoscopic abdominal cerclage. *Obstet Gynecol Clin N Am* 2004;31:497–504.
7. Ghomi A, Rodgers B. Laparoscopic abdominal cerclage during pregnancy: a case report and a review of the described operative techniques. *J Min Invasive Gynecol* 2006;13:337–41.
8. Carter J, Soper D. Laparoscopic abdominal cerclage. *J Soc Laparoendoscopic Surg* 2005;491–3.
9. Benson RC, Durfee RB. Transabdominal cervico uterine cerclage during pregnancy for the treatment of cervical incompetency. *Obstet Gynecol* 1965;25:145–55.
10. Dharia SP, Falcone T. Robotics in reproductive medicine. *Fertil Steril* 2005;84:1–11.